

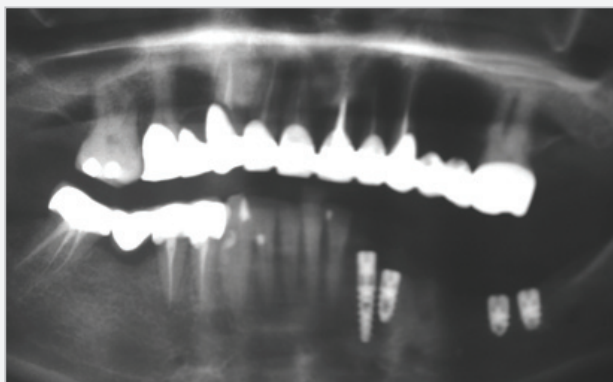Fig. 12 Case 3 - Panoramic x-ray after insertion.

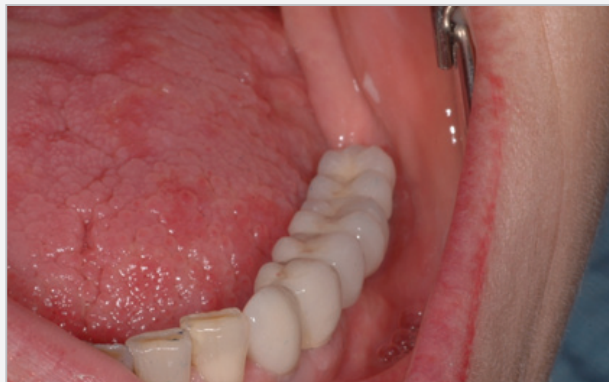

Fig. 15 Case 3

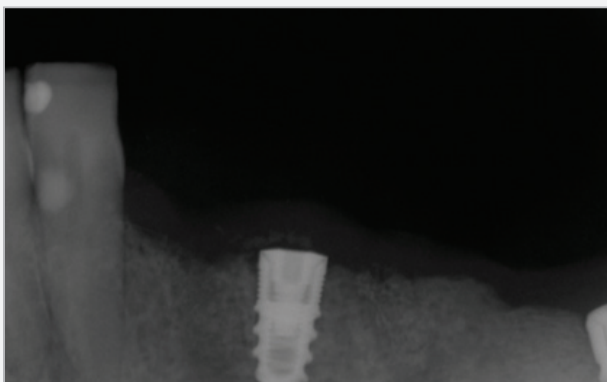

Fig. 13 Case 3 - The implant in position 3,3 was lost because of residual infection and replaced by a 3mm I 13mm UNO implant after 2 months. During this period the other implants recieved a resin provisional restauration. 2X 4,2mm L6.

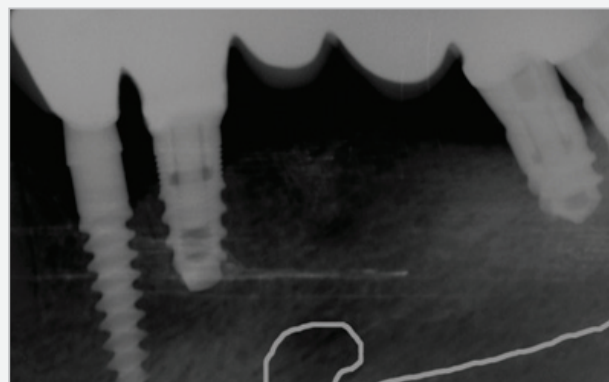


Fig. 16 Case 3 - Intraoral x-ray at 6 months after bridge fixation. See the direction of the mandibular nerve.

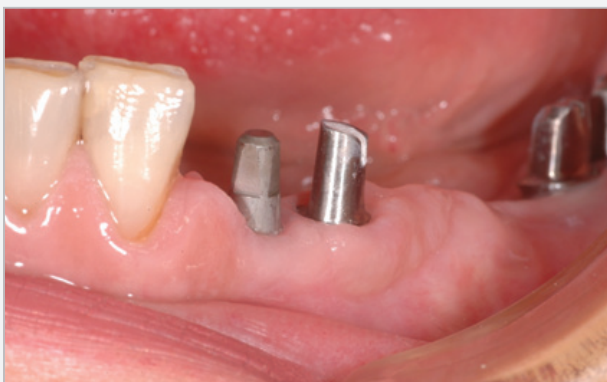

Fig. 14 Case 3

The Use Of 6mm Long Implants In Cases With Limited Bone Height: A Preliminary 6-Month Clinical Study

Olimpiu L.Karancsi¹, Radu Sita¹, Emanuel A. Bratu¹

Background

Limited bone height restricts the use of standard length implants. Short implants may be used in these cases as an alternative for lengthy and expensive augmentation procedures. Recent clinical studies indicate that short implants may support prosthetic restorations quite adequately, but still clinical

documentation is sparse. The purpose of this study was to evaluate the clinical behavior of short implants in reduced bone conditions. The hypothesis was: "Short implants in atrophied jaws are able to result in similar long-term survival rates compared with standard implants.

Materials And Method

Study was approved by IRB (Helsinki).

Subjects - Twenty three implants were placed in 11 patients in different clinical situations. All patients were healthy and with good oral hygiene, but smoking was not an exclusion criterion. Twenty three 6mm implants (Seven, MIS Implants, Bar-Lev, Israel) diameter 4,2mm,

¹Department of Implant restorations University of Medicine and Pharmacy Timisoara Romania

Clinical case presentation: **Case 1**

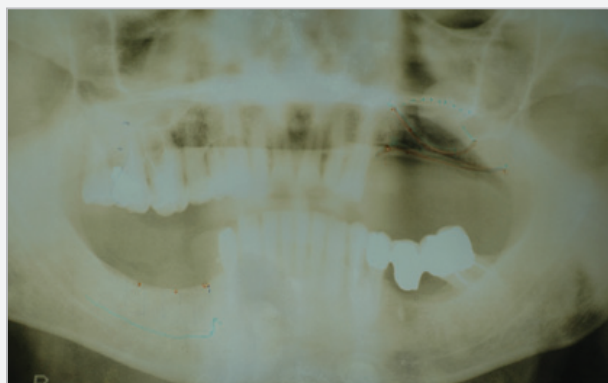


Fig. 1 Case 1 - Preoperative x-ray. Note the reduced bone height above the mental foramen.

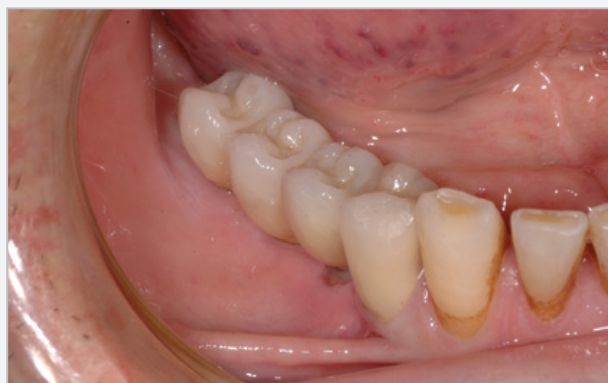

Fig. 3 Case 1 - Final restoration in position.

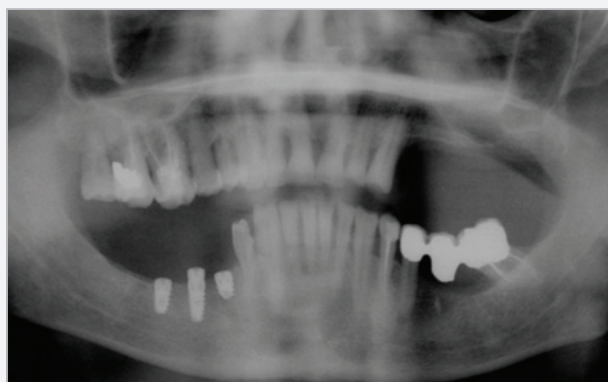


Fig. 2 Case 1 - Postoperative x-ray with the 4,2 6mm Seven implant in position.