



Our Research is Your Success...

This study was
not sponsored
by MIS!

August
2011

Published in:

JOMI

”

Reference-Based Digital Concept to Restore Partially Edentulous Patients Following an Immediate Loading Protocol: A Pilot Study”

Ali Tahmaseb, DDS, PhD/Renaat De Clerck, DDS/Steven Eckert, DDS,
MS/Daniel Wismeijer, DDS, PhD

* Ali Tahmaseb, DDS, University of Amsterdam, The Netherlands
Renaat De Clerck, DDS, Mayo Clinic College of Medicine, Rochester, Minnesota
Steven Eckert, DDS, MS, Minneapolis, Minnesota
Daniel Wismeijer, DDS, PhD, University of Amsterdam, The Netherlands



¹Ali Tahmaseb
²Renaat De Clerck
³Steven Eckert
⁴Daniel Wismeijer

Reference-Based Digital Concept to Restore Partially Edentulous Patients Following an Immediate Loading Protocol: A Pilot Study”

ABSTRACT.

Purpose

To describe the use of a computer-aided three-dimensional planning protocol in combination with previously placed reference elements and computer-aided design/computer-assisted manufacture (CAD/CAM) technology to restore the partially edentulous patient.

Materials and Methods

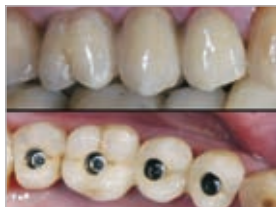Mini-implants and/or reference brackets were inserted or positioned in specified locations in a test cast and in two patients prior to imaging to act as definitive fiducial markers. This served as a fixed base to better define a setup for the fabrication of a surgical template used during computed tomographic imaging. A simulated partially edentulous maxilla was used for the study, and two partially edentulous patients participated. With the CT images, a CAD/CAM superstructure was created prior to surgery and inserted immediately after surgery. Fit of the prosthesis was assessed using three-dimensional tension measurements with strain gauges.

Results

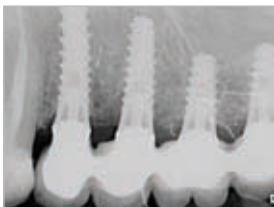
Results: Mean misfit for all implants in the x-, y-, and z-axes was 26.6, 24.8, and 10.4 μm , respectively. The total misfit calculated according to the Pythagorean theorem was 42.6 μm .

Conclusion

Based upon this pilot study in two patients and an in vitro analysis, it appears that the use of reproducible fiducial markers consisting of mini-implants and reference brackets results in the fabrication of an acceptably accurately fitting definitive prosthesis prior to implant placement. *Int J Oral Maxillofac Implants* 2011;26:707–717.



Superstructures in place on the implant level (no abutments) immediately after implant insertion.



One-year postoperative radio-graphs.

Authors' affiliations

¹ Ali Tahmaseb, DDS, University of Amsterdam, The Netherlands.

² Renaat De Clerck, DDS, Mayo Clinic College of Medicine, Rochester, Minnesota.

³ Steven Eckert, DDS, MS, Minneapolis, Minnesota.

⁴ Daniel Wismeijer, DDS, PhD, University of Amsterdam, The Netherlands.