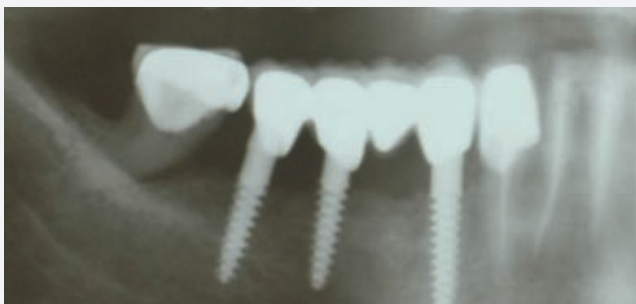

25

News No.25 January 2011

Soft Tissue Healing
Around One Piece
Implants: A Two
Years Retrospective
Clinical Study



mis[®]
Make it Simple

Soft Tissue Healing Around One Piece Implants: A Two Years Retrospective Clinical Study

Olimpiu L.Karancsi¹, Radu Sita¹, Emanuel A. Bratu¹

Abstract

One piece implants were introduced many years ago, however in the last years they were accepted as a treatment option for specific clinical cases. *Aim* - The aim of the study was to evaluate the probing depth values around one piece screw implants with a rough surface neck two years after loading

Methods

Forty one-piece dental implants were placed in twenty-three patients in various clinical situations. The implants were followed for two years after loading. Bone and soft tissue values were evaluated using panoramic x-rays and standard clinical measurements.

Results

All Implants showed good clinical stability two years after loading. Soft tissue adherence was very good on the implant's neck. In cases with rigorous oral hygiene no bleeding on probing was observed. The mean bone loss was 1.8 mm at the end of the study.

Conclusion and discussion

Soft tissue healing around one-piece implants with a rough surface neck was eventless, with no irritation or bleeding after two years. The results suggest that an implant neck with rough surface is appropriate for soft tissue healing.

Materials And Method

One-piece implants (MIS Uno, MIS Implants, Bar-Lev, Israel) with diameter of 3.0 mm (length 10 and 13mm) were clinically evaluated in this study. The 40 implants were placed in 24 patients in different clinical situations. The patients were all with narrow alveolar ridges but with sufficient bone height. No bone augmentation procedures were performed. The patients were all healthy, with good oral hygiene, however smoking was not an exclusion criteria.

Surgical Procedure

The implants were placed following the manufacturer protocol, with the use of a 2mm pilot drill and a 2.4mm final drill. In the

¹Department of Implant supported restorations University of Medicine and Pharmacy Timisoara Romania

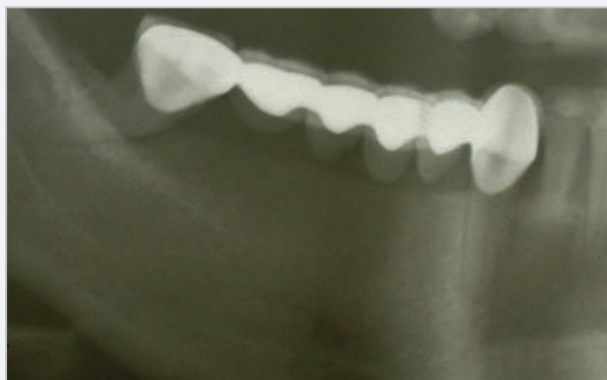

Fig. 1 Preoperative view, narrow ridge, 4,5mm at top of the crest.

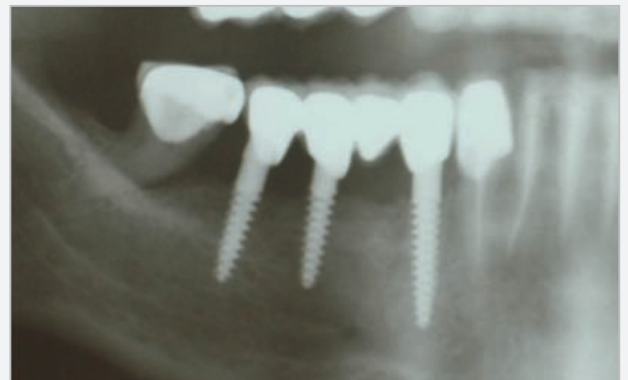


Fig. 3 2 Year postoperative x-ray.

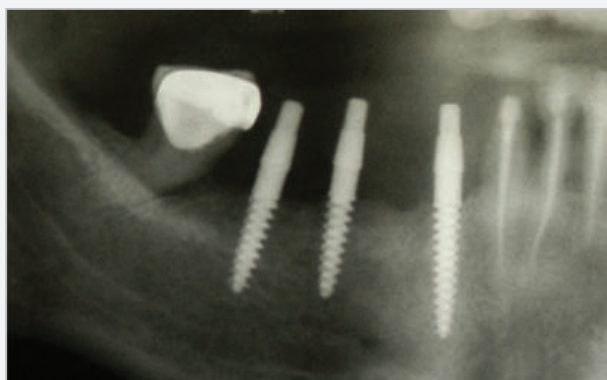


Fig. 2 Postoperative x-ray with 2 3mm diameter, length 10mm, and one 13mm, 3mm diameter UNO implants.

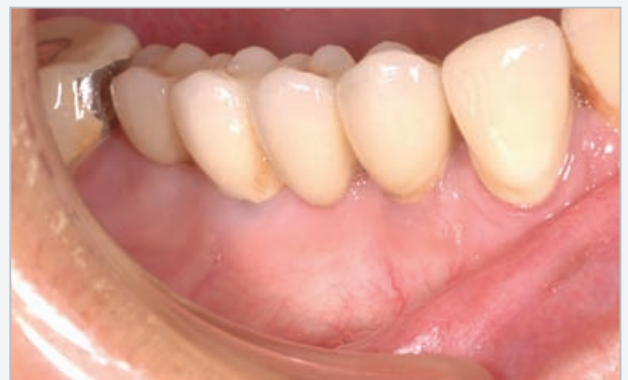

Fig. 4 Final restauration at 2 years.

Nr	Age	Sex	Size	Position	Periostest value	Probing depth			
						Insertion	3 Months	One Year	Two Years
1	145	F	3/13	36	-1	4	2	2	2
			3/13	37	0	3	1,5	1	2
2	50	M	3/13	43	-3	3	1,5	1	1
3	47	M	3/10	12	+1	3,5	2	1	1
4	62	M	3/13	45	-4	4	2	2	2
5	51	M	3/10	22	+2	4	1,5	2	2,5
			3/13	24	+1	3	2	1,5	2
6	37	F	3/10	14	0	3	1	1	1
7	33	M	3/10	21	1	4	2	2	2,5
			3/10	35	2	3	1	1	1,5
			3/10	36	2	2	2	1,5	2
8	54	F	3/13	34	0	5	3	3	3,5
			3/13	35	1	3	2	2	3
			3/13	36	1	5	2,5	2	2
			3/10	44	2	4	2,5	2	2
			3/10	45	0	6	4	3,5	4
9	23	F	3/13	12	1	3	3	3	2
			3/13	22	-1	4	3	2	2
10	21	M	3/10	15	2	-	-	-	-
11	44	M	3/10	34	2	4	4	3	3
			3/10	36	1	3,5	3	2	2

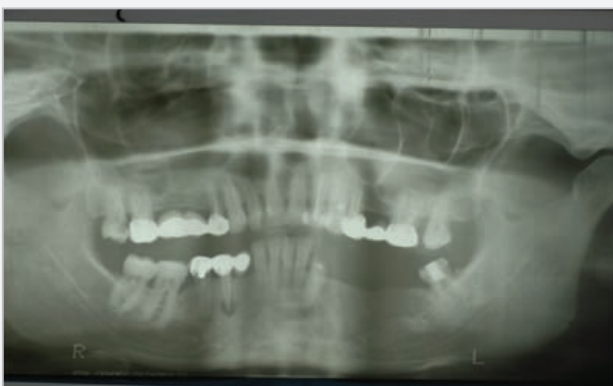

Fig. 5a. Preoperative x-ray. Narrow mandibular ridge.

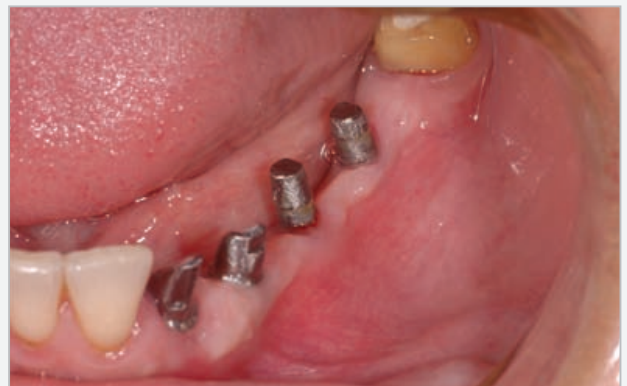

Fig. 6a. Parodontometer AESCULAP measuring device. Note the perfect soft tissue healing after removal of the provisional restoration.

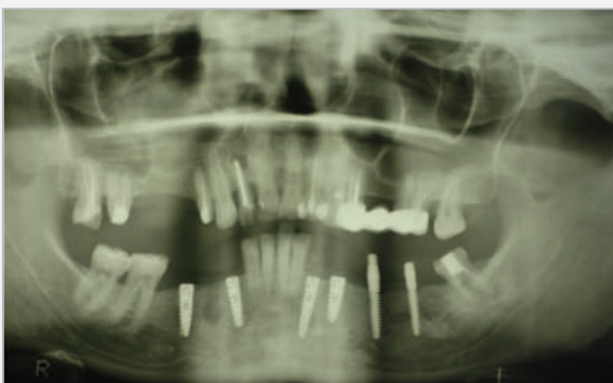

Fig. 5b. Preoperative x-ray. Narrow mandibular ridge.

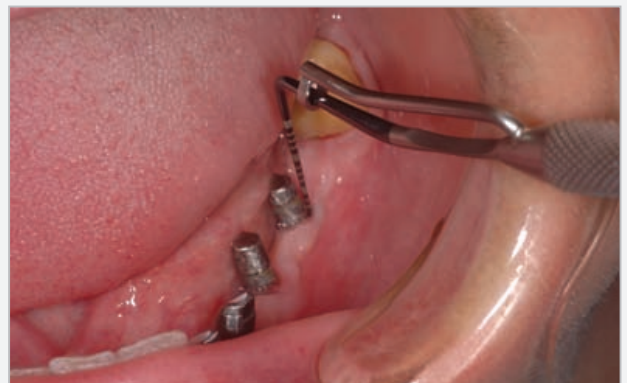

Fig. 6a. Parodontometer AESCULAP measuring device. Note the perfect soft tissue healing after removal of the provisional restoration.

Nr	Age	Sex	Size	Position	Periotest value	Probing depth			
						Insertion	3 Months	One Year	Two Years
12	37	F	3/10	43	0	2	2	2	2.5
			3/13	44	-1	6	5	4	4
			3/13	45	-2	5	2.5	2	2
13	29	M	3/10	24	0	4	5	4	5
14	22	M	3/13	45	-2	5	4	3	4
			3/13	46	-1	3	3	2	2
15	36	F	3/10	45	0	3	2	3	3
			3/10	46	0	4	4	4	5
			3/13	33	1	3	3.5	3	3.5
			3/13	35	2	2.5	2	1.5	2
16	20	F	3/10	14	0	4	3	3	3
			3/10	15	1	5	4	3	3
17	56	F	3/10	12	1	3	2	2	3
18	50	F	3/13	25	-4	3	1.5	3	4
19	36	F	3/10	34	+2	3	2	1.5	2
20	58	M	3/13	43	+1	3.5	2	2	3
21	45	M	3/10	44	0	4	1.5	4	5
22	50	M	3/10	22	+2	4	2	2	3
23	43	M	3/13	14	+1	3	1	4	6

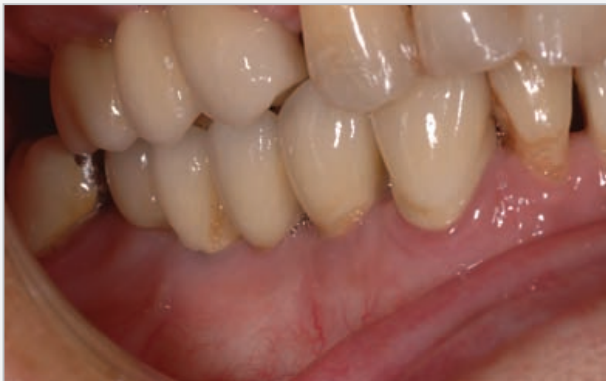

Fig. 7 Final restauration at one year after insertion.

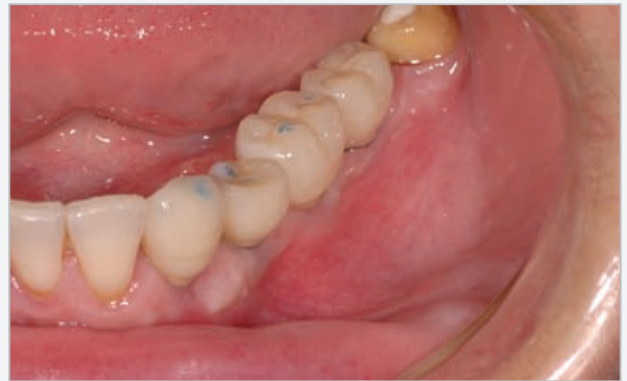

Fig. 10 Occlusion check of the final restauration.

maxilla, the final drill was only used in the cortical bone. A crestal incision was performed and full mucoperiosteal flaps were elevated at the site. Bone was cleaned of periosteal tissue and implant position was marked by a round bur. Then 2mm pilot drill marked the depth and angulation of the implant. For the first 2 mm depth, 2.4mm final drill was used in the cortical crestal bone. Implants were inserted using a ratchet, until final position was reached. This position was considered right below the abutment, the threads being completely covered by bone. Medication included antibiotics (Augmentin 1gr Smithkline Beecham) for 6 days and analgesics (Ketonal forte 200mg) for 3 days. Probing depths around the implants were performed after sutures placement. Measurements were taken at the distal point of the alveolar crest around each implant with a periodontal probe. Bone level and soft tissue level were considered baseline at insertion. Patients returned after 3 days and depending on periosteal values a decision was made whether to immediately restore the implant or not. All patients with negative periosteal values received restorations; otherwise, waiting time was 3 months. The immediate restorations were made of acrylic resin and cemented with provisional Temp-Bond cement (Kerr). After this period, another probing depth measurement was taken and compared to data from the day of surgery.

Follow Up And Examination

Soft tissue sounding was performed at insertion, at three months after placement, at one year after placement and at two years after placement. Sounding was performed using a parodontometer by Aesculap 0,2 N (20g). Measurements were made on the distal surface of the implant.

Results

One of the 40 implants failed during the osseointegration phase, probably due to the fact that the bone was extremely narrow at the site. All other 39 implants showed good stability during the 2 years study period. The mean value of bone loss on x-rays was 1,8mm. At the first year, probing depths tended to decrease (as shown on table 1) however, at the 2 year follow-up probing depths were generally higher than after the values found at the end of the first year. This is probably due to bone remodeling around the implant's neck in narrow ridges. In patients with good oral hygiene no bleeding on probing was observed when using the parodontometer Aesculap. There was no significant difference between male and female patients.

Discussion

The present clinical study evaluated the stabilization of soft tissue around a rough SLA treated surface. At the initial examination after implant insertion, probing depths showed greater values comparing to the values obtained after 3 months. This is normal, because of the

healing process of the peri-implant tissues. What is of clinical value is the fact that there was no irritation of the soft tissues around the implants during the healing period which suggests that regardless of receiving a provisional or not, the gingiva recovers well and adheres on a rough surface, if certain criterias are accomplished.

One piece implants with a SLA surface showed very good tissue integration, especially for the soft tissue at the implant neck. This type of implant has even today a large range of uses in almost every clinical situation, presenting a minimal bone loss and allowing insertion in narrow ridges. Large augmentation procedures can be avoided. Even after 2 years of loading no significant modifications of tissue around the implants were visible. Also the prosthetic procedures are simple in case of good positioning of the implants. A problem that can occur in time is that in the case of implant loss and abutment preparation, implant unscrewing can be difficult. This is why sufficient prosthetic space has to be created before implant insertion. Also, the clinician must be aware that only minor changes in implant insertion axis can be obtained with abutment preparation. For that reason, careful preoperative evaluation should be performed and occlusion check should be made after pilot drilling.

The bone of patients differs significantly in quantity and quality and soft tissue is following these structures. Very often, patients refuse augmentative procedures, which are costly and sometimes involve significant risk factors. Therefore, the use of one piece implants with reduced diameter is still a treatment option even today, in the era of subgingival healing. One major problem of modern implant dentistry is maintaining soft tissue around dental implants. This problem is especially of great interest in the aesthetic zone. Several methods of soft tissue management evolved in the last decades, with emphasis on soft tissue transpositions and transplants. These procedures are not always in reach of the general practitioner. Implant's design has a great influence on bone and soft tissue level, as showed in different studies. In the last 5 years, the polished neck of dental implants is loosing ground in favor of treated surfaces. Until now, most studies concentrated on bone level around implants, but this is also linked with soft tissue adherence. The fact that a 3mm implant neck allows softer tissue around it is undoubted. The question is whether a polished neck is beneficial.

Conclusions

The study demonstrated that there is no absolute need of a polished implant neck in order to prevent peri-implant tissue irritation, if a fixed gingiva around the implant can be obtained. Because of the small diameter of the implants it is possible in almost every case to obtain sufficient soft tissue thickness around the implant. Also, if the pocket depth depends on the thickness of the mucosa, the thicker the mucosa, the smaller the depth. However, if the gingiva is not fixed, problems of plaque deposits can arise and implant failure is possible.

Suturing technique is also important. Two interrupted sutures should be positioned very close to the implant's abutment to avoid gaps between implant and tissue. Initial results are promising, but further investigation and longer observation periods are needed in order to have a statement on this issue.

The most indicated position for this implant type is that of mandibular lateral and central incisors, maxillary lateral incisors especially for aesthetic reasons and mandibular narrow ridges, when conditions do not allow augmentation procedures. This type of implant is not indicated in edentulous patients due to the risk of mechanical overload.

References

1. Early Clinical Experience With a New One-Piece Implant System in Single Tooth Sites S.Parel, S.Schow. Journal of Oral and Maxillofacial Surgery, Volume 63, Issue 9, Pages 2-10
2. The Single-Piece Milled Titanium Implant Bridge, Stephen M. Parel Issue Date: February 2003, Posted On: 8/2/2005 www.dentistrytoday.com
3. One-Piece Root-Form Implants: A Return to Simplicity. Jack Hahn Journal of Oral Implantology 2005: Vol. 31, No. 2, pp. 77-84.
4. Evaluation of the adaptation interface of one-piece implant-supported superstructures obtained in Ni-Cr-Ti and Pd-Ag alloys Heloisa M6derna Ferreira da Costa; Renata Cristina Silveira Rodrigues, Maria da Gl6ria Chiarello de Mattos, Ricardo Faria Ribeiro Braz. Dent. J. vol.14 no.3 Ribeir6o Preto 2003.
5. Osseointegration of one-piece zirconia implants compared with a titanium implant of identical design: a histomorphometric study in the dog. F. P. Koch, D. Weng, S. Kr6mer, S. Biesterfeld, A. Jahn-Eimermacher and W. Wagner Clinical Oral Implants Research Volume 21 Issue 3, Pages 350 – 356 Published Online: 13 Jan 2010
6. Flapless Implant Placement with Crown Lengthening Procedure to Correct Crown Height: A Case Report Implant Dentistry: Jacobson Nancy, Starr Cliff October 2009 - Volume 18 - Issue 5 - pp 387-392
7. Early Clinical Experience With a New One-Piece Implant System in Single Tooth Sites Stephen M. Parel, Sterling R. Schow LOMS Volume 63, Issue 9, Supplement, Pages 2-10 (September 2005)
8. Minimally Invasive Surgery Procedures With One Piece Implants: A new Biologic Philosophy in Implant Therapy Georg Dr6ke Acta stomatologica Croatica, Vol.42 No.1 March 2008
9. Delayed versus immediate loading of implants: Survival analysis and risk factors for dental implant failure Susarla S.M., Chuang, S.K., Dodson T.B. J Oral Maxillofac Surg; Dental Implantology Update February 01, 2008
10. Retentive Force of the Konus Telescope on One-piece Implant Kobayashi Mariko, Ohkubo Chikahiro, Shimpo Hidemasa, Ishikawa Yasutaka, Kurihara Daisuke, Hosoi Toshio, Murata Toshiyuki Prosthodontic Research & Practice 7(2), 216-218, 20080701

MIS's Quality System complies with international quality control standards: ISO 13485:2003 - Quality Management System for Medical Devices, ISO 9001: 2008 - Quality Management System and CE Directive for Medical Devices 93/42/EEC. MIS's products are cleared for marketing in the USA and CE approved.

© MIS Corporation. All rights Reserved

MC-N2511 Rev.1

The logo for MIS (MIS Implants Technologies) features the lowercase letters 'mis' in a white, sans-serif font. The letter 'i' is positioned above the 's', and a registered trademark symbol (®) is located to the upper right of the 's'. The entire logo is set against a dark brown background.

MIS Implants Technologies Ltd.
www.mis-implants.com